



# EUROPEAN NEUROLOGICAL REVIEW

VOLUME 6 • ISSUE 4 • WINTER 2011 • EXTRACT

---

## **Transcutaneous Vagus Nerve Stimulation**

Jens Ellrich

*Professor of Medical Physiology, Department of  
Health Science and Technology, Medical  
Faculty, Aalborg University  
and Chief Medical Officer, Medical Department,  
cerbomed GmbH*

---

## Transcutaneous Vagus Nerve Stimulation

Jens Ellrich

Professor of Medical Physiology, Department of Health Science and Technology, Medical Faculty, Aalborg University  
and Chief Medical Officer, Medical Department, cerbomed GmbH

### Abstract

Invasive vagus nerve stimulation (VNS) is an approved treatment for drug-resistant epilepsy. Besides its recognised clinical efficacy, there are major drawbacks, such as invasiveness and a great many side effects. Therefore there is a medical demand for transcutaneous VNS (t-VNS®), which combines selective, non-invasive access to vagus nerve afferents with a low risk profile. Both treatments excite thick myelinated fibres of vagus nerve branches that project to the nucleus of the solitary tract in the brainstem. Preclinical data emphasise the equivalent anticonvulsive effects of both methods. Based upon the common mode of action and the first clinical data, the t-VNS device received Conformité Européenne (CE) approval. Besides the approved intended use for drug-resistant epilepsy and depression, a future clinical trial will address the efficacy of t-VNS in chronic pain.

### Keywords

Anticonvulsive, brainstem, concha, depression, drug-resistant, ear, epilepsy, neuromodulation, non-invasive, pain, vagus nerve

**Disclosure:** Jens Ellrich is Chief Medical Officer at cerbomed GmbH.

**Received:** 10 August 2011 **Accepted:** 23 September 2011 **Citation:** *European Neurological Review*, 2011;6(4):262–4

**Correspondence:** Jens Ellrich, Chief Medical Officer, Medical Department, cerbomed GmbH, Medical Valley Centre, Henkestrasse 91, D-91052 Erlangen, Germany.  
E: jens.ellrich@cerbomed.com

**Support:** The publication of this article was funded by cerbomed GmbH

Drug-resistant epilepsy accounts for more than 30 % of epileptic patients.<sup>1</sup> Alternative treatment options are resective neurosurgery, deep brain stimulation and invasive vagus nerve stimulation (VNS).<sup>2</sup> Invasive stimulation of the cervical branch of the vagus nerve has been shown to be highly effective in clinical trials, with a responder rate of approximately 60 %.<sup>3,4</sup> Surgically and technically induced complications include electrode fractures, deep wound infections, transient vocal cord palsy, cardiac arrhythmia under test stimulation, electrode malfunction and post-traumatic dysfunction of the stimulator.<sup>5</sup> Frequent side effects of chronic invasive VNS, such as hoarseness, cough, dyspnoea and pain, are mainly due to bidirectional stimulation of efferent and afferent fibres within the mixed cervical branch of the vagus nerve.

Besides the recognised clinical efficacy of invasive VNS, there are major drawbacks, such as invasiveness, and a great many side effects, due to electrical stimulation of a mixed peripheral nerve. Therefore there is a medical demand for an alternative medical device that combines selective, non-invasive access to vagus nerve afferents with a low risk profile.<sup>6</sup>

This article assesses the new neuromodulatory technique of transcutaneous VNS (t-VNS®) on the basis of the following requirements for effective VNS therapy inferred from recent concepts of the mechanisms of action:<sup>3,4,7</sup>

- unidirectional stimulation of thick myelinated afferent vagus nerve fibres;

- access to the nucleus of the solitary tract (NTS) in the brainstem; and
- elicitation of a typical cerebral activation pattern.

### Site of Transcutaneous Vagus Nerve Stimulation

t-VNS targets the cutaneous receptive field of the auricular branch of the vagus nerve (ABVN) at the outer ear. Several lines of evidence from anatomical and clinical studies reveal the topographical anatomy and the functional impact of the ABVN on the autonomic nervous system.

### Nerve Supply of the Outer Ear

The human outer ear (see *Figure 1A*) is supplied by three sensory nerves, namely the auriculotemporal nerve, the great auricular nerve and the ABVN.<sup>8</sup> On 14 human ears the complete course of nerve supply was exposed and each branch was defined by identifying its origin. In 73 % of cases the ABVN, and in 18 % the great auricular nerve, were found on the antihelix solely and 9 % showed a double innervation. In 9 % of specimens the ABVN provided ramification for the crura antihelices, in 45 % for the cavity of conchae and in 100 % for the cymba conchae. In 55 % the ABVN and the great auricular nerve were found on the cavity of conchae. No region with triple innervation was found. Thus, in all specimens the ABVN was found to significantly supply the cavity of conchae and exclusively supply the cymba conchae.

### Intracranial Section of the Vagus Nerve

A patient with tongue cancer suffered from severe pain in the outer ear. This refractory pain was treated by intracranial section

of the vagus nerve (see *Figure 1B*).<sup>9</sup> During the sectioning of the vagus on the left side, the anaesthetist noted that the heart rate dropped to 40 beats per minute. Following section of the vagus root, the cutaneous area of complete anaesthesia covered the posterior wall of the external auditory canal, the concha and, with only a slight degree of pain, the antihelix and antitragus. The authors concluded that there is no doubt that the major supply to the anaesthetised area is by means of the vagus nerve.<sup>9</sup>

### Isolated Vagus Nerve Palsy with Herpes Zoster

A 31-year-old woman was admitted to hospital due to difficulty swallowing fluid, hoarseness and painful vesicles on the right ear. Neurological examination revealed poor elevation of the soft palate on the right side. Herpetic vesicles were present on the right concha and the posterior wall of the external auditory canal. No facial palsy, loss of hearing or mucosal lesions in the mouth or pharynx were present. The authors diagnosed an isolated vagus nerve palsy due to varicella zoster infection (see *Figure 1C*), highlighting the distribution of the cutaneous receptive field of the ABVN.<sup>10</sup>

### Auricular Syncope

A 13-year-old girl had been receiving drug treatment for presumed absence epilepsy without any anticonvulsive effect. The medical history indicated that recurrent syncopal attacks were precipitated by external auditory canal stimulation. Targeted autonomic function tests confirmed a hyperactive vagal response with bradycardia and light-headedness provoked by tactile stimulation of the left external auditory canal. Abstinence from ear-scratching led to complete alleviation of symptoms without any drug treatment. The authors proposed reflex syncope (see *Figure 1D*), due to stimulation of the ABVN, as the pathophysiological mechanism.<sup>11</sup>

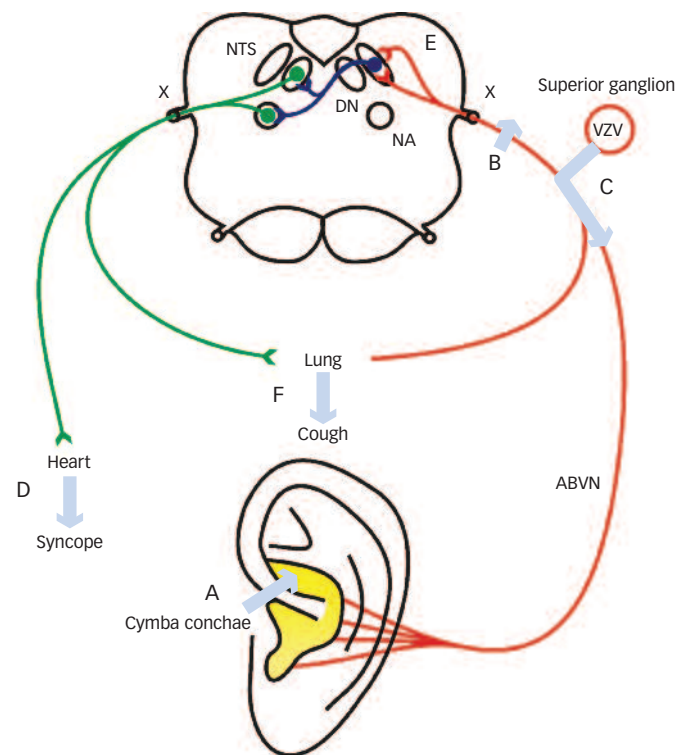
### Referred Otalgia

Referred otalgia arises from non-otological, remote diseases and occurs in up to 50 % of adult patients who consult a general physician for ear pain.<sup>12</sup> Head and neck malignancy is the most important pathology associated with referred otalgia. Twenty-six patients with non-metastatic lung cancer primarily suffered from auricular pain localised ipsilaterally to the lung mass.<sup>13</sup> Lung masses which abut or infiltrate visceral vagus nerve afferents can refer pain to the ear by convergence of visceral fibres from the lung and somatic afferents of the ABVN onto common secondary sensory neurons in the NTS (see *Figure 1E*).

### Ear-cough Reflex

A young boy complained about a chronic dry cough. On examination, an accumulation of epidermal cerumen surrounding a skin ulceration in a narrowed external auditory canal was found. Stimulation of the wall of the ear canal with a cotton bud triggered a marked cough reflex (see *Figure 1F*). After removal of the accumulated cerumen the cough disappeared.<sup>14</sup> The ear-cough reflex was elicited in 12 patients. It was bilaterally induced in three patients. Lacrimation was additionally observed in one patient (auriculo-lacrimal reflex).<sup>15,16,17</sup> Twenty-one out of 500 patients studied had a clinically positive ear-cough reflex. Gagging and lacrimation were seen in nine and 10 patients, respectively. While vomiting was present in one case (ear-vomiting reflex), severe cardiac inhibition with syncopal attack was seen in three patients (auriculo-cardiac reflex).<sup>15</sup> Similar reflex phenomena documenting

**Figure 1: Brainstem Mechanisms of Transcutaneous Vagus Nerve Stimulation**



Sensory fibres of the auricular branch of the vagus nerve (ABVN) (red) supply the skin of the concha (yellow). The cymba conchae is exclusively supplied by the ABVN. Sensory vagus nerve fibres from different organs project via the superior ganglion to the nucleus of the solitary tract (NTS). NTS neurons (dark blue) project to visceral efferent neurons located in the dorsal nucleus of the vagus nerve (DN) and the nucleus ambiguus (NA). Visceral efferent nerve fibres (green) supply, e.g., the heart and the lung. For the sake of clarity, afferent pathways and efferent pathways of the vagus nerve are separately illustrated on the right and left sides of the figure, respectively. A to F refer to the text. VZV = varicella zoster virus causing herpes zoster; X = vagus nerve.

the functional connection between the ABVN and the autonomic nervous system are the gastro-auricular phenomenon, the auriculo-genital reflex and the auriculo-uterine reflex.<sup>18</sup>

### Preferential Excitation of Thick Myelinated Nerve Fibres by Transcutaneous Vagus Nerve Stimulation

The clinical efficacy of VNS requires activation of thick myelinated afferent fibres of the vagus nerve.<sup>4,7</sup> The fibres of a sensory peripheral nerve such as the ABVN mediate touch sensation. Consequently, the stimulus intensity of electrical t-VNS is adjusted to a level above the individual's detection threshold and clearly below the individual's pain threshold. The detection threshold is defined as the lowest stimulus intensity that evokes the first perceptible sensation that reliably corresponds to a tingling sensation. The pain threshold is defined as the lowest stimulation intensity that elicits the first pricking or unpleasant sensation. Both psychophysical thresholds are determined by the method of limits, with several runs of electrical stimuli applying ramps of decreasing and increasing intensity. In 18 healthy volunteers (36 ears) the electrical detection threshold with a single-pulse stimulation (200  $\mu$ s duration) averages out at  $0.8 \pm 0.3$  mA in the cymba conchae.<sup>19</sup> This intensity conforms to published thresholds as measured in the face or the forearm.<sup>20-22</sup> Touch sensation is clinically assessed by the mechanical detection threshold via application of von Frey filaments. The mechanical detection



threshold in the area of the cymba conchae in 14 ears corresponds to  $0.5 \pm 0.7$  mN which is very similar to thresholds in the face and the forearm.<sup>19,21,23</sup> Electrical and mechanical detection thresholds and evoked tingling sensation in patients and volunteers clearly demonstrate preferential activation of thick myelinated A $\beta$  fibres of the ABVN by t-VNS.

### Projection of Auricular Branch of the Vagus Nerve Fibres to the Nucleus of the Solitary Tract

The NTS is the main target of VNS (see *Figure 1*). Central projections of the ABVN of the cat were examined by the transganglionic horseradish peroxidase (HRP) transport technique. After topical application of HRP to the central cut end of the ABVN, neuronal somata in the superior ganglion of the vagus nerve were labelled. Main terminal labelling was seen ipsilaterally in the NTS. Within the NTS, labelled terminals were detected in the interstitial, dorsal, dorsolateral and commissural subnuclei.<sup>24</sup> In rats, HRP was injected into the middle of the ear for anterograde tracing in order to identify ABVN fibre endings in the brainstem. HRP immunohistochemistry showed positive fibre endings in the NTS.<sup>25</sup>

### Cerebral Activation Pattern under Vagus Nerve Stimulation

t-VNS was applied to 22 healthy volunteers in a functional magnetic resonance imaging (fMRI) study.<sup>26</sup> Stimulation of the earlobe served as a sham control. fMRI showed robust blood oxygen level-dependent (BOLD) signal decreases in limbic brain areas, including the amygdala, hippocampus, parahippocampal gyrus and the middle and superior temporal gyrus under t-VNS. Increased activation was detected in the insula, precentral gyrus and the thalamus. Earlobe stimulation as a sham control intervention did not show similar effects. The brain activation pattern under t-VNS clearly shares features with changes observed during invasive VNS.<sup>27</sup>

### Anticonvulsive Effect of Transcutaneous Vagus Nerve Stimulation in Rodents

The anticonvulsive effect of t-VNS was addressed in an experimental rat seizure model.<sup>28</sup> Epileptic seizures were induced by intraperitoneal injection of the proconvulsant compound pentylenetetrazole (PTZ). Seizures were documented by epidural electroencephalogram (EEG) recording. Invasive VNS was applied to the left cervical branch of the vagus nerve and t-VNS was administered to the left ear. PTZ injection without any VNS evoked highly synchronous, large-amplitude activity in epidural EEG traces. Invasive VNS and t-VNS both substantially reduced PTZ-induced seizure activity in epidural EEG compared with that of control periods. There was no significant difference between invasive VNS and t-VNS in the average duration of the anti-seizure effect.<sup>28</sup>

### Reduced Seizure Frequency in a Case Series of Drug-resistant Epilepsy

t-VNS was applied to seven patients with drug-resistant epilepsy for a period of nine months. Patients applied t-VNS three times per day for a time period of one hour each. The primary outcome of the study was based upon the number of seizures as documented by the patient's seizure diary. After nine months, an overall reduction in seizure frequency was observed in five out of seven patients. The authors concluded that non-invasive t-VNS is a safe and well-tolerated method for longer time periods and might be an alternative treatment option for epilepsy patients.<sup>29</sup>

### Summary and Conclusions

Invasive VNS and t-VNS both excite thick myelinated fibres of vagus nerve branches that project to the NTS in the brainstem. Preclinical data emphasise the equivalent anticonvulsive effects of both neuromodulatory methods. Based upon the common mode of action and the first clinical data, the t-VNS device received Conformité Européenne (CE) approval. Besides the approved intended use for drug-resistant epilepsy and depression, a future clinical trial will address the efficacy of t-VNS in chronic pain.<sup>30</sup> ■

- Kwan P, Arzimanoglou A, Berg AT, et al., Definition of drug resistant epilepsy: consensus proposal by the ad hoc Task Force of the ILAE Commission on Therapeutic Strategies, *Epilepsia*, 2010;51:1069-77.
- Al-Otaibi FA, Hamani C, Lozano AM, Neuromodulation in Epilepsy, *Neurosurgery*, 2011;69:957-79.
- Beekwilder JP, Beems T, Overview of the clinical applications of vagus nerve stimulation, *J Clin Neurophysiol*, 2010;27:130-8.
- Amar AP, Levy ML, Liu CY, Apuzzo MLJ, Vagus Nerve Stimulation. In: Krames ES, Peckham PH, Rezai AR (eds), *Neuromodulation*, first edition, London: Academic Press, 2009;625-37.
- Spuck S, Tronnier V, Orosz I, et al., Operative and technical complications of vagus nerve stimulator implantation, *Neurosurgery*, 2010;67:489-94.
- Ventureyra EC, Transcutaneous vagus nerve stimulation for partial onset seizure therapy. A new concept, *Childs Nerv Syst*, 2000;16:101-2.
- Vonck K, Boon P, Van Roost D, Anatomical and physiological basis and mechanism of action of neurostimulation for epilepsy, *Acta Neurochir Suppl*, 2007;97:321-8.
- Peucker ET, Filler TJ, The nerve supply of the human auricle, *Clin Anat*, 2002;15:35-7.
- Fay T, Observations and results from intracranial section of glossopharyngeus and vagus nerves in man, *J Neurol Psychopathol*, 1927;8:110-23.
- Ohashi T, Fujimoto M, Shimizu H, Atsumi T, [A case of isolated vagus nerve palsy with herpes zoster], *Rinsho Shinkeigaku*, 1994;34:928-9.
- Thakar A, Deepak KK, Kumar SS, Auricular syncope, *J Laryngol Otol*, 2008;122:1115-7.
- Charlett SD, Coatesworth AP, Referred otalgia: a structured approach to diagnosis and treatment, *Int J Clin Pract*, 2007;61:1015-21.
- Eross EJ, Dodick DW, Swanson JW, Capobianco DJ, A review of intractable facial pain secondary to underlying lung neoplasms, *Cephalalgia*, 2003;23:2-5.
- Jegoux F, Legent F, Beauvillain de Montreuil C, Chronic cough and ear wax, *Lancet*, 2002;360:618.
- Gupta D, Verma S, Vishwakarma SK, Anatomic basis of Arnold's ear-cough reflex, *Surg Radiol Anat*, 1986;8:217-20.
- Tekdemir I, Aslan A, Elhan A, A clinico-anatomic study of the auricular branch of the vagus nerve and Arnold's ear-cough reflex, *Surg Radiol Anat*, 1998;20:253-7.
- Fernandez-Fernandez FJ, Iglesias-Ollerios MA, Chronic cough in adults, *Thorax*, 2004;59:451.
- Engel D, The gastroauricular phenomenon and related vagus reflexes, *Arch Psychiatr Nervenkr*, 1979;227:271-7.
- Ellrich J, Transcutaneous vagus nerve stimulation: feasibility, safety and clinical application, *Neuromodulation*, 2011;14:in press.
- Ellrich J, Lamp S, Peripheral Nerve Stimulation Inhibits Nociceptive Processing: An Electrophysiological Study in Healthy Volunteers, *Neuromodulation*, 2005;8:225-35.
- Ristic D, Spangenberg P, Ellrich J, Analgesic and antinociceptive effects of peripheral nerve neurostimulation in an advanced human experimental model, *Eur J Pain*, 2008;12:480-90.
- Aymanns M, Yekta SS, Ellrich J, Homotopic long-term depression of trigeminal pain and blink reflex within one side of the human face, *Clin Neurophysiol*, 2009;120:2093-9.
- Yekta SS, Smeets R, Stein JM, Ellrich J, Assessment of trigeminal nerve functions by quantitative sensory testing in patients and healthy volunteers, *J Oral Maxillofac Surg*, 2010;68:2437-51.
- Nomura S, Mizuno N, Central distribution of primary afferent fibers in the Arnold's nerve (the auricular branch of the vagus nerve): a transganglionic HRP study in the cat, *Brain Res*, 1984;292:199-205.
- Gao XY, Rong P, Ben H, et al., Morphological and electrophysiological characterization of auricular branch of vagus nerve: Projections to the NTS in mediating cardiovascular inhibition evoked by the acupuncture-like stimulation, *Abstr Soc Neurosci*, 2010;694:22.
- Kraus T, Hosl K, Kiess O, et al., BOLD fMRI deactivation of limbic and temporal brain structures and mood enhancing effect by transcutaneous vagus nerve stimulation, *J Neural Transm*, 2007;114:1485-93.
- Chae JH, Nahas Z, Lomarev M, et al., A review of functional neuroimaging studies of vagus nerve stimulation (VNS), *J Psychiatr Res*, 2003;37:443-55.
- He W, Zhu B, Rong P, A new concept of transcutaneous vagus nerve stimulation for epileptic seizure, *Abstr Soc Neurosci*, 2009;539:4.
- Stefan H, Kreiselmeier G, Kerling F, et al., Transcutaneous vagus nerve stimulation (t-VNS) in pharmacoresistant epilepsies: a proof of concept trial, *Epilepsia*, 2011 (under revision).
- Ellrich J, Busch V, Eichhammer P, Inhibition of pain processing by transcutaneous vagus nerve stimulation, *Neuromodulation*, 2011;14:383.